



The pattern of residual tumor after neoadjuvant chemotherapy for locally advanced esophageal cancer and its clinical significance

Department of Gastroenterological Surgery, Graduate School of Medicine

Assistant Professor Tomoki Makino https://researchmap.jp/_-_-_-

Professor Yuichiro Doki <https://researchmap.jp/ydoki3251>



Abstract

Objectives: To investigate the residual pattern of esophageal cancer in the esophageal wall after neoadjuvant chemotherapy (NAC) and its clinical significance.

Background: NAC is a standard treatment for locally advanced esophageal cancer; however, residual tumor patterns in resected specimens after NAC and their clinico-pathological characteristics remain unknown.

Methods: One hundred twenty consecutive patients with cT3 or deeper esophageal cancer underwent curative esophagectomy after NAC and achieved grade 2 histological responses between 2000 and 2016. Hematoxylin- eosin staining of residual tumor sections revealed 4 remnant categories: Type 1: shallow, Type 2: central, Type 3: deep, and Type 4: diffuse. We examined associations between these Types and clinico-pathological factors, including prognosis.

Results: Forty-five (38%) specimens had no residual tumor cells in the mucosal layer. The adventitia layer displayed the lowest residual tumor cell frequency (18%) among all layers. Types 1, 2, 3, and 4 residual tumor patterns were found in 49 (41%), 33 (28%), 9 (8%), and 29 (24%) patients, respectively. Type 4 showed the maximum standard uptake value after NAC; Types 3 and 4 had higher ratios of venous invasion than Type 1 or 2. Patients with Type 3 or 4 more frequently developed pleural dissemination or distant metastasis than patients with Type 1 or 2. Survival was similar among the 4 Types.

Conclusions: After NAC for locally advanced esophageal cancer, the shallow residual tumor pattern was most common, but approximately 40% of specimens showed no tumor cells in the mucosal layer. Deep and diffuse remnant patterns were associated with high risks of pleural dissemination and distant metastasis.

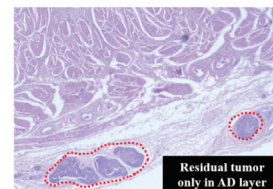
Notably, patients with Type 3 or 4 residual tumors more frequently developed pleural dissemination or distant metastasis, compared to patients with Type 1 or 2; however, no significant difference in survival was observed among patients with the 4 residual tumor types.

Significance of the research and Future perspective

In the present study, we found that the most common residual tumor pattern after NAC for advanced esophageal cancer was a shallow remnant type. We also found that, in approximately 40% of cases, tumor cells were absent in the mucosal layer, which indicated that it would be difficult to diagnose a clinical CR (complete response), based solely on an endoscopic mucosal biopsy after NAC. Finally, we showed that deep or diffuse remnant types were associated with a high positive rate of venous invasion and a high risk of developing pleural dissemination or distant metastasis after curative surgery. To the best of our knowledge, this study was the first to evaluate residual tumor patterns after NAC and their associations with clinico-pathological factors, and might contribute to optimizing treatment strategies, and to eventually improving survival in patients with advanced esophageal cancer

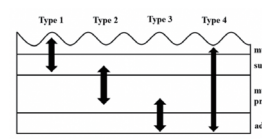
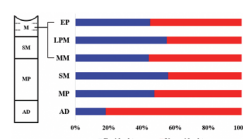
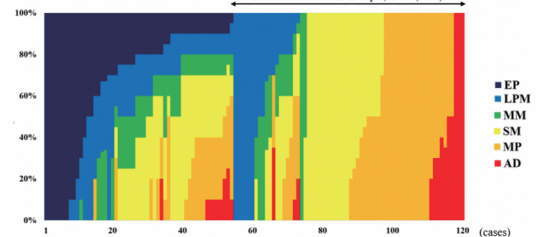
Background & Results

NAC is a standard treatment for locally advanced esophageal cancer; however, residual tumor patterns in resected specimens after NAC and their clinico-pathological characteristics remain unknown. In the present study, we evaluated tumor regression patterns in a total of 120 resected specimens from cT3 or deeper esophageal cancer that showed grade 2 histological responses to NAC. We found no residual tumor cells in the EP layers in 55.0% of cases and no residual cancer cells in the mucosal layers in 37.5% of patients. Residual tumor cells were found at a lower frequency (18.3%) in the AD layer than in any other layers. Patients with type 2 residual tumors showed higher rates of endoscopic CR diagnosis, and patients with Types 2 and 3 residual tumors showed significantly less macroscopic ulceration, compared to patients with the other residual tumor types. These findings were consistent with the pathological examinations of the resected specimens. Types 3 and 4 residual tumors displayed a significantly higher percentage of venous invasion compared to Types 1 and 2 residual tumors.



no residual tumor in mucosal layer, n=45 (38%)

no residual tumor in EP layer, n=66 (55%)



Patent

Treatise

URL

Keyword

Hashimoto, T; Makino, T; Yamasaki, M. et al. The Pattern of Residual Tumor After Neoadjuvant Chemotherapy for Locally Advanced Esophageal Cancer and Its Clinical Significance. *Ann Surg.* 2020 May; 271(5): 875-884. doi: 10.1097/SLA.0000000000003129.

https://resou.osaka-u.ac.jp/en/research/2018/20190110_2

esophageal cancer, neoadjuvant chemotherapy, patterns of residual tumor, recurrence site